Estimation of Severity

The severity of PS is assessed using the peak velocity and maximum pressure gradient across the pulmonary valve via CW Doppler (see Fig. 9.42). The criteria for defining the various grades of PS based on these values are listed in Table 9.6.

While the application of the continuity and PISA principles for the calculation of the pulmonary valve area (PVA) is theoretically feasible, these methods have not been validated for PS. In addition, the significance of the PVA for determining the various grades of severity of PS has not been described; therefore, calculation of the PVA is not useful in the assessment of PS severity.

The most common error in the estimation of pressure gradients relates to suboptimal alignment of the ultrasound beam with the PS jet. Another caveat is the presence of increased velocities and pressure gradients, secondary to increased flow across the pulmonary valve in the absence of PS. For example, increased velocities across the pulmonary valve may be encountered when there is an atrial septal defect, a ventricular septal defect or significant pulmonary regurgitation. In these cases, the transpulmonary velocities are increased secondary to an increased stroke volume across the valve; therefore, careful interrogation of the pulmonary valve leaflets and motion is required to determine if coexistent PS is also present.

Measurement of the Pulmonary Annulus

The procedure of choice for patients with severe or symptomatic congenital PS is balloon pulmonary valvuloplasty. In order to determine the optimal balloon size for successful dilatation of the valve, the size of the pulmonary annulus needs to be measured prior to the procedure. Measurement of the pulmonary annulus is best achieved from a zoomed parasternal long or short axis view of the RVOT (Fig. 9.50, top). Colour flow Doppler imaging may also be useful in delineating the lateral border of the RVOT (Fig. 9.50, bottom).

Estimation of Pulmonary Artery Systolic Pressure

In the absence of PS or RVOT obstruction, it is assumed that the RVSP is the same as the pulmonary artery systolic pressure (PASP). However, when there is RVOT obstruction or PS, the RVSP will be greater than the PASP as flow always travels from a higher pressure to a lower pressure area.

In particular, the RVSP will be equal to the sum of the PASP and the pressure gradient across the pulmonary valve (Fig. 9.51):

Equation 9.5

$$RVSP = PASP + \Delta P_{RV\text{-}PA}$$

where RVSP = right ventricular systolic pressure (mm Hg)
PASP = pulmonary artery systolic pressure (mm Hg)
$\Delta P_{RV\text{-}PA}$ = systolic pressure gradient between the RV and PA (mm Hg)

Therefore, by rearranging the above equation, the PASP can be derived:

Equation 9.6

$$PASP = RVSP - \Delta P_{RV\text{-}PA}$$

where PASP = pulmonary artery systolic pressure (mm Hg)
RVSP = right ventricular systolic pressure (mm Hg)
$\Delta P_{RV\text{-}PA}$ = systolic pressure gradient between the RV and PA (mm Hg)

> Significant PS can be virtually excluded by the presence of a normal RVSP. When there is significant PS, the RVSP must be elevated as a higher RVSP is required to open the stenotic pulmonary valve. As such, the RVSP cannot be normal in patients with significant PS.

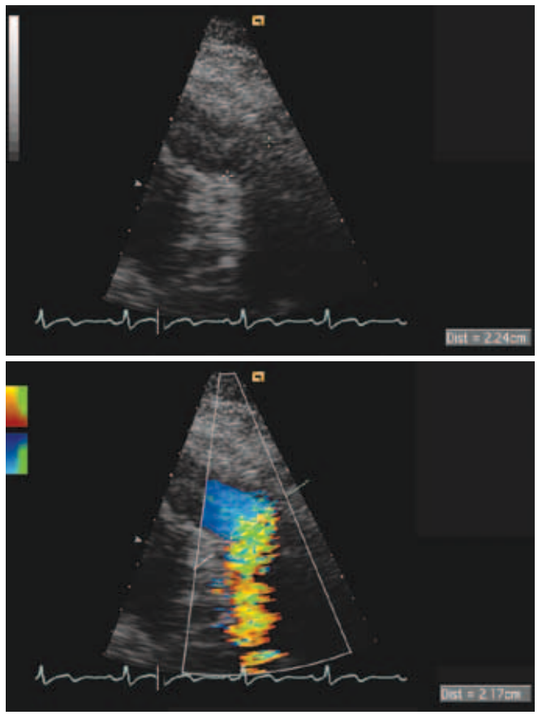

Figure 9.50 This zoomed view of the right ventricular outflow tract was recorded from the parasternal short axis view. The pulmonary annulus is measured during systole using the inner edge to inner edge technique (*top*). Using colour Doppler imaging, the borders of the pulmonary annulus may be enhanced to facilitate the measurement of the annulus (*bottom*).

Table 9.6 Recommendations for Classification of Pulmonary Stenosis Severity

	Mild PS	Moderate PS	Severe PS
Peak velocity (m/s)	< 3	3 – 4	> 4.0
Maximum Gradient (mm Hg)	< 36	36 - 64	> 64

Source: Baumgartner H, Hung J, Bermejo J, Chambers JB, Evangelista A, Griffin BP, Iung B, Otto CM, Pellikka PA, Quinones M; American Society of Echocardiography; European Association of Echocardiography. Echocardiographic assessment of valve stenosis: EAE/ASE recommendations for clinical practice. *J Am Soc Echocardiogr,* Vol. 22(1), page 20, © 2009 with permission from Elsevier.

As illustrated in Figure 9.51, the RVSP and the PASP do not peak at the same point in time and for this reason, the systolic pressure gradient between the RV and PA ($\Delta P_{RV\text{-}PA}$) is referred to as the peak-to-peak pressure gradient. Therefore, the PASP is equal to the difference between the RVSP and the peak-to-peak pressure gradient across the pulmonary valve. Importantly, the peak-to-peak pressure gradient is different to the Doppler-derived pressure gradient which measures the maximum instantaneous pressure gradient between the RV and the PA at the same instant in the cardiac cycle. So in order to estimate the PASP via Doppler, the Doppler gradient that best correlates with the peak-to-peak pressure gradient is required; in most instances, this has been shown to be the mean pressure gradient [9.4]. Therefore, the PASP via Doppler can be estimated as:

Equation 9.7

$$PASP = RVSP - mPG_{PV}$$

where PASP = pulmonary artery systolic pressure (mm Hg)
RVSP = right ventricular systolic pressure (mm Hg)
mPG_{PV} = mean pressure gradient across the pulmonary valve (mm Hg)

However, in patients with very severe or critical PS, the Doppler maximum instantaneous pressure gradient and the peak-to-peak pressure gradient correlate extremely well. This is because in critical PS the pulmonary pressure waveform becomes quite 'flat', therefore the maximum instantaneous Doppler gradient and the peak-to-peak pressure gradient are very similar (Fig. 9.52). Therefore, in patients with critical PS, the PASP is estimated as the difference between the RVSP and the maximum instantaneous Doppler gradient across the valve:

Equation 9.8

$$PASP_C = RVSP - MIPG_{PV}$$

where $PASP_C$ = pulmonary artery systolic pressure in critical pulmonary stenosis (mm Hg)
RVSP = right ventricular systolic pressure (mm Hg)
$MIPG_{PV}$ = maximum instantaneous pressure gradient across the pulmonary valve (mm Hg)

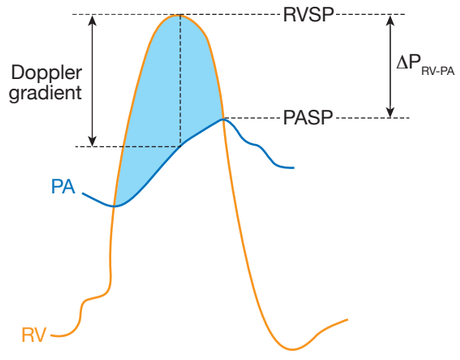

Figure 9.51 This schematic illustrates the right ventricular (RV) and pulmonary artery (PA) pressure traces in pulmonary stenosis. The pressure difference between the right ventricular systolic pressure (RVSP) and the pulmonary artery systolic pressure (PASP) is equivalent to the systolic pressure gradient between the RV and PA ($\Delta P_{RV\text{-}PA}$). Observe that the RVSP peaks before the PASP; for this reason, the pressure gradient between the RV and PA is also referred to as the peak-to-peak pressure gradient.

Critical PS can be identified based on the shape of the Doppler profile (Fig. 9.53). In critical PS, the Doppler profile across the pulmonary valve appears rounded with the peak velocity occurring in mid systole.

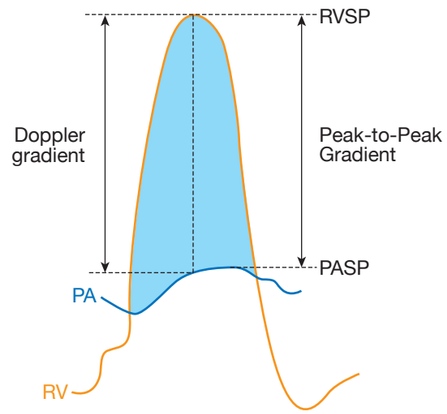

Figure 9.52 This schematic illustrates the right ventricular (RV) and pulmonary artery (PA) pressure traces in critical pulmonary stenosis. Observe that the Doppler-derived pressure gradient and the invasively-derived peak-to-peak pressure gradient are very similar due to damping and 'flattening' of the PA pressure trace.

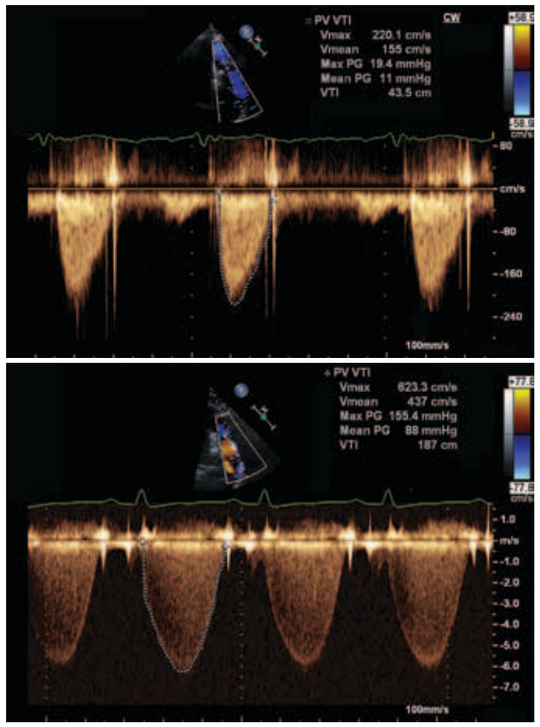

Figure 9.53 In patients with mild-moderate pulmonary stenosis (PS), the PS jet is V-shaped and the velocity peaks in early systole (*top*). In patients with critical PS, the PS jet appears rounded and the velocity peaks in mid systole (*bottom*); this occurs due to 'flattening' of the pulmonary pressure waveform as shown in Figure 9.52.

[9.4] Silvilairat S, Cabalka AK, Cetta F, Hagler DJ, O'Leary PW. Echocardiographic assessment of isolated pulmonary valve stenosis: which outpatient Doppler gradient has the most clinical validity? *J Am Soc Echocardiogr.* 2005 Nov;18(11):1137-42.