Shortened P½t (or DS) for Significant Semilunar Valve Regurgitation

As stated, the Doppler velocity spectrum reflects the pressure gradient between two chambers or vessels. In AR, the Doppler velocity spectrum represents the pressure gradient between the aorta and left ventricle (LV) during diastole. In the case of PR, the Doppler velocity spectrum represents the pressure gradient between the pulmonary artery and right ventricle (RV) during diastole. The rapidity with which the pressures between the aorta or pulmonary artery and their respective ventricles approach one another can be used to determine the severity of regurgitation.

In AR, the maximum Doppler velocity of the regurgitant signal occurs following aortic valve closure when the pressure difference between the aorta and LV is greatest. The velocities of the Doppler regurgitant signal then decrease over the diastolic period as the pressure difference between the aorta and LV decreases due to: (1) the fall in the aortic diastolic pressure which occurs due to a combination of forward run-off to the periphery as well as regurgitation back into the LV, and (2) the rise in the LV diastolic pressure which occurs due to a combination of normal transmitral inflow and the aortic regurgitant volume into the LV. With mild AR, the early diastolic pressure gradient is high and this pressure gradient then gradually declines over the diastolic period due to a gradual decline in the aortic diastolic pressure and only a small increase in the LV end-diastolic pressure (LVEDP) (Fig. 13.9, left). As a result, the decline in the AR deceleration slope over diastole is gradual.

In the presence of acute, severe AR, two important pressure changes occur: (1) the aortic diastolic pressure falls rapidly, and (2) the LVEDP increases markedly. This results in rapid decline or decay of the pressure gradient over the diastolic period (Fig. 13.9, right). As a result, the decline in the AR deceleration slope over diastole falls rapidly.

This same concept can also be applied to the assessment of PR. That is, when there is mild PR there is a gradual decline in the PR deceleration slope over diastole; when there is severe PR in association with significant increase in the RV end-diastolic pressure (RVEDP), there is a rapid decline of the PR deceleration slope over the diastolic period.

The rate of decline of the AR velocity spectrum can be measured using either the DS or, more commonly, the P½t (Fig. 13.10). The DS is derived from the peak velocity and the deceleration time (DT) and can be expressed as:

Equation 13.1

$$DS = V_{peak} \div DT$$

where DS = deceleration slope (m/s^2)
V_{peak} = peak velocity (m/s)
DT = deceleration time (s)

Measurement of the P½t is analogous to that used in the Doppler assessment of mitral stenosis. Recall that the P½t is defined as the time required for the pressure to decay to half its original value (see Chapter 12). In Doppler, velocity rather than pressure is displayed on the Doppler spectrum. Since velocity and pressure are related, the P½t can be measured from the velocity spectrum as:

Equation 13.2

$$V½ = \frac{V_{peak}}{\sqrt{2}} = \frac{V_{peak}}{1.414}$$

where V1/2 = velocity corresponding to one-half the peak pressure(m/s)
V_{peak} = peak velocity (m/s)

The P½t is also related to the DT such that the P½t is equal to 29% of the DT:

Equation 13.3

$$P½t = 0.29 \times DT$$

where P½t = pressure half-time (ms)
DT = deceleration time (ms)

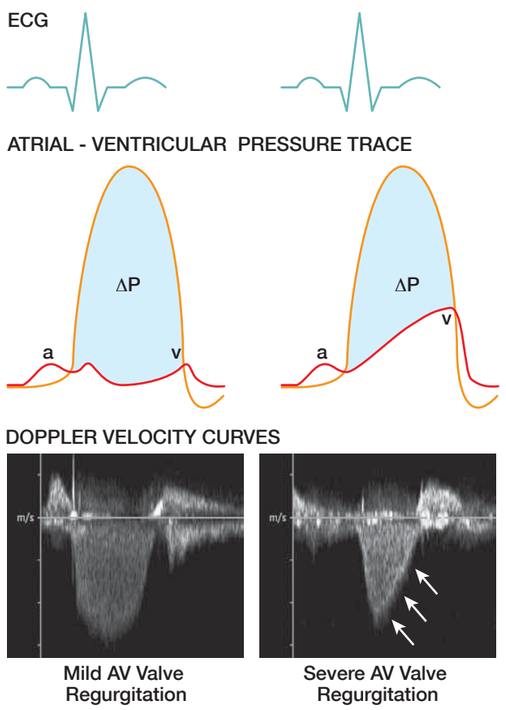

Figure 13.8 In AV valve regurgitation, the regurgitant Doppler velocity signal reflects the pressure difference (ΔP) between the ventricle and the atrium during systole. The top schematics illustrate the pressure tracings of the atrium and ventricle during systole while the Doppler velocity spectra corresponding to these traces are displayed below. The atrial pressure trace consists of an a-wave which represents an increase in atrial pressure with atrial contraction and a v-wave which represents an increase in atrial pressure, with venous return into the atrium, during ventricular systole. In mild AV valve regurgitation (*left*), the ΔP between the ventricle and atrium from early to late systole is relatively high; this results in a symmetrical, parabolic Doppler velocity curve. With severe AV valve regurgitation with an increase in the atrial V-wave pressure (*right*), the ΔP between the ventricle and atrium is high from early to mid-systole as for mild AV valve regurgitation. However, toward the latter half of systole there is a decrease in the ΔP between the ventricle and atrium; this results in a rapid and asymmetric, V-shaped Doppler velocity curve (*triple arrows*).

Limitations of the contour of the regurgitant Doppler signal as an indicator of significant regurgitation relate to other factors that also affect the contour of the signal. Importantly, the contour of the regurgitant Doppler signal only reflects the pressure gradient between two chambers. Therefore, other factors that affect the pressures within these chambers besides the regurgitant volume, such as chamber compliance, may also affect the contour of the regurgitant signal. For example, shortening of the P½t in the absence of significant AR may be seen in patients who have a "stiff", noncompliant LV with an associated increase in the LVEDP.

Furthermore, aortic diastolic pressure decay is not only related to the severity of AR but also to the systemic vascular resistance (afterload). Therefore, an increase in the systemic vascular resistance may result in an increase in the rate of decline of the P½t without any change in regurgitant orifice size. This can also occur in PR where an increase in the pulmonary vascular resistance may result in an increase in the rate of decline of the P½t without any change in regurgitant orifice size.

Another limitation of using the contour as an indirect sign of regurgitation severity is based on poor or inadequate Doppler alignment with regurgitant jets. For example, poor alignment of the ultrasound beam with the direction of the regurgitant jet and/or eccentric jets may underestimate or overestimate the P½t of the regurgitant jet.

Clinical Consideration

The P½t is most useful in the assessment of acute, severe AR. In this situation, the P½t is very short due to the rapid rise in the LVEDP as the LV does not have time to compensate for the marked increase in diastolic volume caused by severe AR. In chronic, severe AR, the P½t is often long as the LV is able to accept a large volume of blood without a significant increase in the LVEDP.

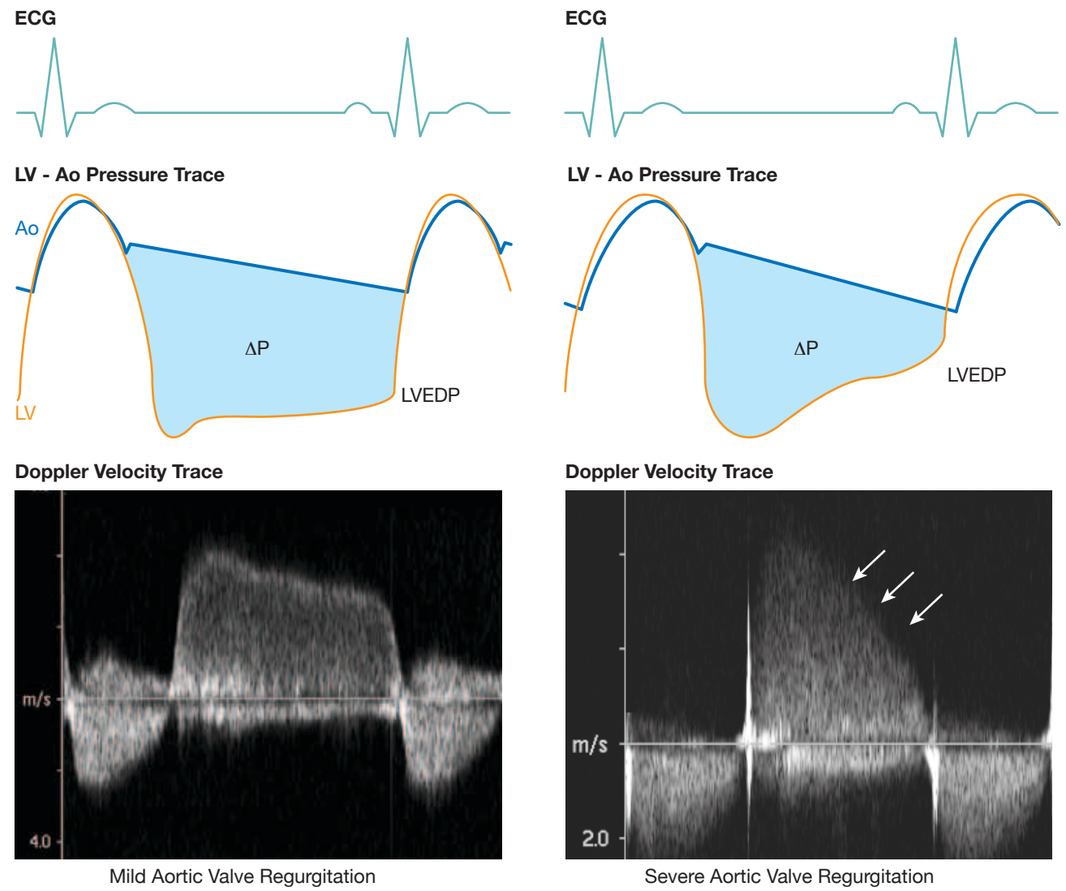

Figure 13.9 The aortic regurgitant (AR) Doppler signal is a function of the pressure gradient (ΔP) between the aorta (Ao) and left ventricle (LV) during diastole. The top schematic illustrates the pressure tracings of the aorta and the LV while the Doppler velocity spectra corresponding to these schematics are displayed below. With mild AR (*left*), the ΔP between the aorta and the LV in early diastole is high. This gradient then gradually decreases throughout diastole due to a gradual decline in the aortic diastolic pressure and only a small increase in the LV end-diastolic pressure (LVEDP). The resultant Doppler spectrum depicts a reasonably 'flat' (prolonged) deceleration slope. With acute, severe AR (*right*), the aortic pressure drops rapidly during diastole and the LVEDP also rises rapidly. This results in a rapid decline (shortening) of the diastolic slope of the regurgitant Doppler velocity curve (*triple arrows*).